

Guidance agreed with Expert Haematology Panel (EHP) April 10th 2021

Guidance agreed with British Society of Neuroradiologists (BSNR) and RCR 11th April 2021

Guidance updated 24th May 2021

Management of patients presenting to the Emergency Department/ Acute Medicine with symptoms 5-42 days post Astra Zeneca vaccine

The condition of concern is Covid-19 Vaccine-induced Immune Thrombosis and Thrombocytopenia (VITT)

VITT is a rare disorder occurring after COVID-19 vaccination that leads to blood clots in multiple organ sites. If left untreated, the risk of death is over 50%.

Cases usually present with progressive thrombosis, with a high preponderance of cerebral venous sinus thrombosis. Splanchnic vein thrombosis is common and pulmonary embolism and arterial ischaemia are also seen. Bleeding can be significant and unexpected. Symptoms of concern are:

- Persistent or severe headaches, seizures or focal neurology,
- Shortness of breath, persistent chest or abdominal pain,
- Swelling, redness, pallor or cold lower limbs

Key Decision point 0 – Does this patient’s presentation raise any concern about VITT?

If no, manage as per routine practice for specific presentation

If yes, continue with this guidance

- People who have previously had VITT may present with recurrent symptoms. They need to be monitored closely. Signs of relapse may be when a patient’s platelet count starts to fall, or they develop new or recurrent symptoms.

Updated 24th May 2021

As this is an emerging area of practice, please continue to check back for updates

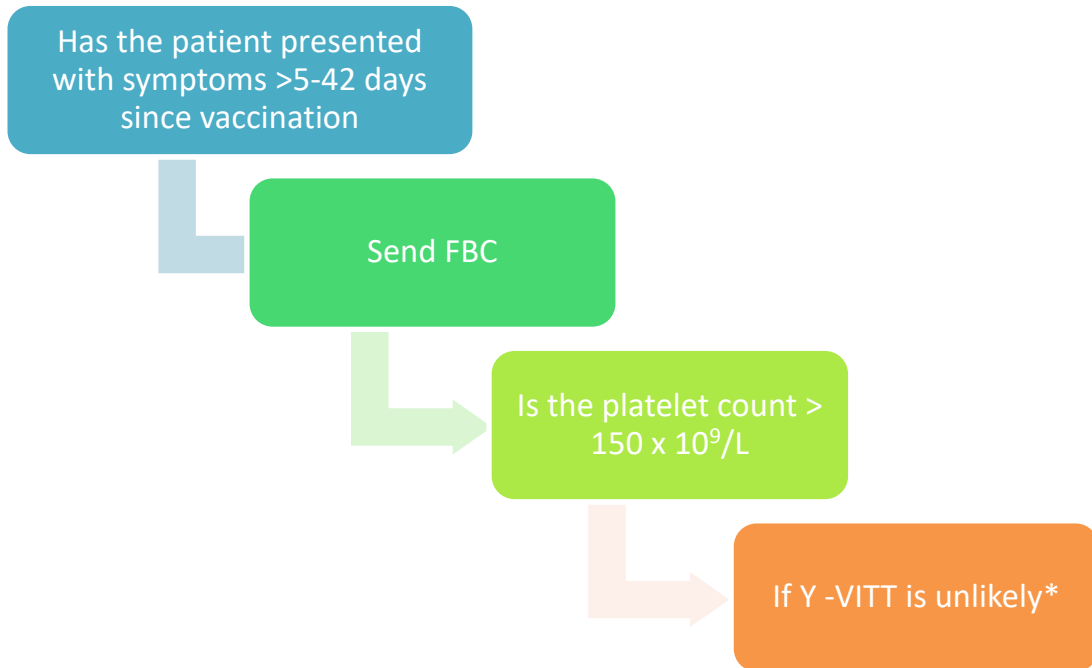
<https://b-s-h.org.uk/> and <https://www.gov.uk/government/organisations/medicines-and-healthcare-products-regulatory-agency>

Guidance agreed with Expert Haematology Panel (EHP) April 10th 2021

Guidance agreed with British Society of Neuroradiologists (BSNR) and RCR 11th April 2021

Guidance updated 24th May 2021

Key Decision point 1 – initial assessment



***Note that in <5% of cases of VITT, the platelet count is normal at presentation and drops later. Therefore, if there is a high index of suspicion in a patient with normal platelets, check D dimer and fibrinogen, and/or consider repeating the platelet count the following day.** Current evidence suggesting the need for a 'high index of suspicion' in this context is day 5-28 post AZ vaccine with new onset headache or abdominal pain which is atypical and severe in nature.

DVT and PE due to VITT have presented clinically as late as day 42.

Updated 24th May 2021

As this is an emerging area of practice, please continue to check back for updates


<https://b-s-h.org.uk/> and <https://www.gov.uk/government/organisations/medicines-and-healthcare-products-regulatory-agency>

Guidance agreed with Expert Haematology Panel (EHP) April 10th 2021

Guidance agreed with British Society of Neuroradiologists (BSNR) and RCR 11th April 2021

Guidance updated 24th May 2021

Key Decision point 2 -is patient safe to go home?



**If presenting with clear thrombotic event (such as stroke, TIA, STEMI, PE, limb or abdominal thrombosis *and* platelets normal, sent fibrinogen, D-dimer and antibodies to Platelet Factor 4 (PF4) repeat platelets the next day while managing as clinically appropriate.

Updated 24th May 2021

As this is an emerging area of practice, please continue to check back for updates

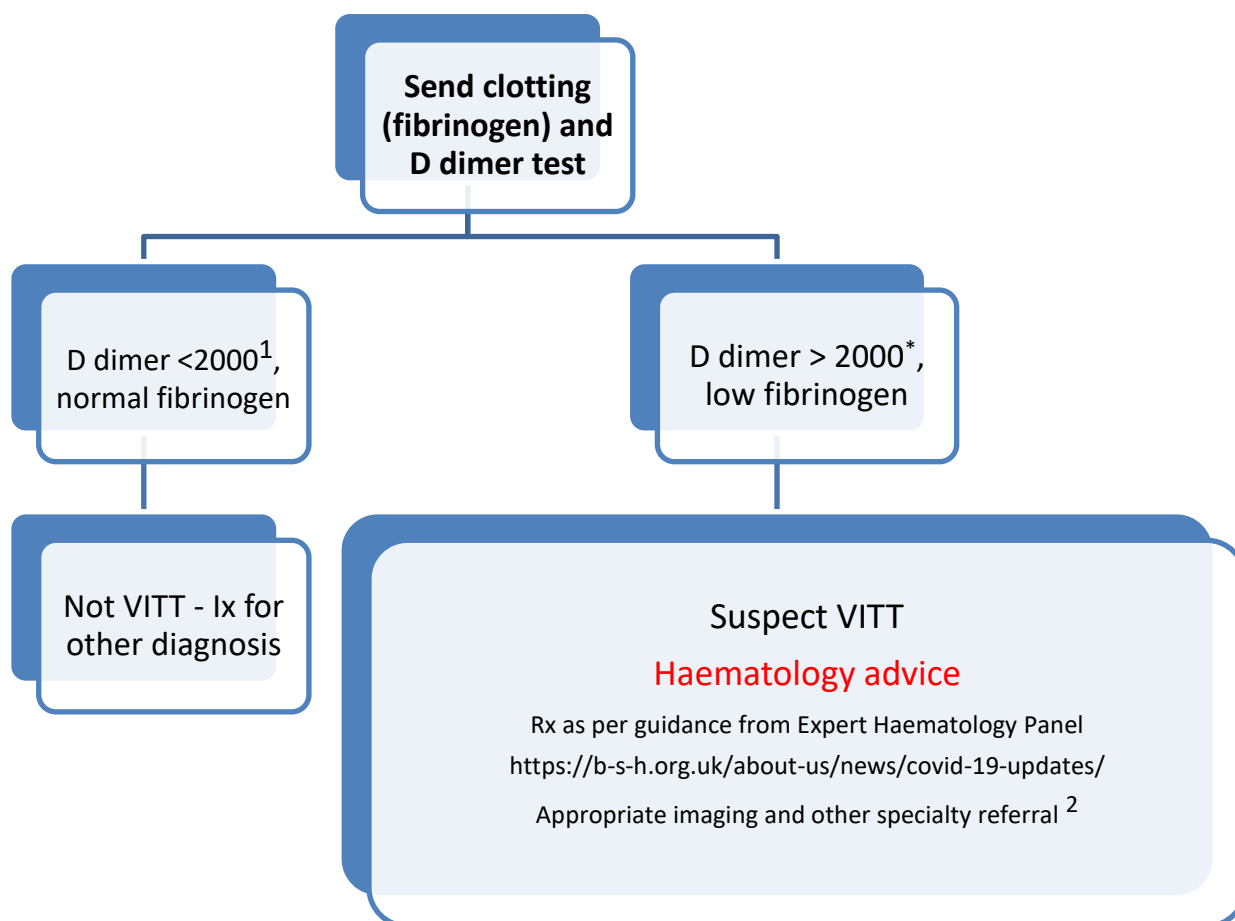
<https://b-s-h.org.uk/> and <https://www.gov.uk/government/organisations/medicines-and-healthcare-products-regulatory-agency>

Guidance agreed with Expert Haematology Panel (EHP) April 10th 2021

Guidance agreed with British Society of Neuroradiologists (BSNR) and RCR 11th April 2021

Guidance updated 24th May 2021

Key Decision point 3- if platelets $< 150 \times 10^9/L$



¹D Dimer as mcg/L, (includes FEU or DDU) = 2mg/L

Definite cases -D Dimers > 4000 mcg/L but D Dimers 2000-4000 mcg/L may need to be considered as a probable case

Updated 24th May 2021

As this is an emerging area of practice, please continue to check back for updates

<https://b-s-h.org.uk/> and <https://www.gov.uk/government/organisations/medicines-and-healthcare-products-regulatory-agency>

Guidance agreed with Expert Haematology Panel (EHP) April 10th 2021

Guidance agreed with British Society of Neuroradiologists (BSNR) and RCR 11th April 2021

Guidance updated 24th May 2021

Presentation	Basic Outcome
AZ but time window not 5-42 days	Home, no follow up (unless needs workup of other diagnosis of concern)
AZ, 5-42 days, platelets >150 x 10⁹	Home with safety net to return for retesting if any exacerbation of symptoms or 'high index of suspicion', (unless needs workup of other diagnosis of concern) Current evidence suggesting the need for a 'high index of suspicion' in this context is day 5-28 post AZ vaccine with new onset headache or abdominal pain which is atypical and severe in nature
AZ, 5-42 days, platelets <150 x 10⁹	Further investigation and work up including D dimer & fibrinogen
Not AZ but another Covid vaccine	VITT is unlikely to be exclusive to AZ and suspicion should be maintained following the other COVID-19 vaccines.

Updated 24th May 2021

As this is an emerging area of practice, please continue to check back for updates

<https://b-s-h.org.uk/> and <https://www.gov.uk/government/organisations/medicines-and-healthcare-products-regulatory-agency>

Guidance agreed with Expert Haematology Panel (EHP) April 10th 2021

Guidance agreed with British Society of Neuroradiologists (BSNR) and RCR 11th April 2021

Guidance updated 24th May 2021

2

Neuroimaging Recommendations

1. If no clinical and haematological features of VITT are present, headache symptoms should be managed via usual headache pathways, with neuro-imaging only if clinically appropriate. Cerebral venography is not generally indicated.
2. For patients **WITH** VITT and headache symptoms, dedicated cerebral venous imaging is appropriate.
 - i. Non-contrast CT brain combined with contrast enhanced CT cerebral venography is rapid, accessible and has very high diagnostic accuracy.
 - ii. MR/MR venography is an equally accurate alternative and may be preferred in some centres.

Other Radiology imaging in discussion with radiology – CTPA/ CT Abdo as required by clinical suspicion.

Updated 24th May 2021

As this is an emerging area of practice, please continue to check back for updates

<https://b-s-h.org.uk/> and <https://www.gov.uk/government/organisations/medicines-and-healthcare-products-regulatory-agency>