



Royal College
of Surgeons
of England

ADVANCING SURGICAL CARE



Royal College
of Physicians



The Royal College of
Emergency Medicine



THE ROYAL
COLLEGE OF
SURGEONS
OF EDINBURGH



ROYAL COLLEGE OF
PHYSICIANS AND
SURGEONS OF GLASGOW



RCSI

Diagnosis and management of gastrointestinal manifestations of vaccine induced thrombosis & thrombocytopenia (VITT) syndrome

Intercollegiate Multidisciplinary Guidance for Clinicians

4 May 2021

Supported and endorsed by:

Royal College of Surgeons of England (RCSE)
Royal College of Physicians (RCP)
Royal College of Radiologists (RCR)
Royal College of Emergency Medicine (RCEM)
Royal College of Physicians & Surgeons of Glasgow (RCPSG)
Royal College of Surgeons of Edinburgh (RCSEd)
Royal College of Surgeons in Ireland (RCSI)

Developed in collaboration with:

Association of Coloproctology of Great Britain and Ireland (ACPGBI)
Association of Surgeons of Great Britain and Ireland (ASGBI)
Association of Upper Gastrointestinal Surgery of Great Britain and Ireland (AUGIS)
British Association for Study of the Liver (BASL)
British Society of Gastroenterology (BSG)
British Society of Gastrointestinal and Abdominal Radiology (BSGAR)
British Society of Interventional Radiology (BSIR)
Expert Haematology Panel (EHP)
Vascular Society of Great Britain and Ireland (VSGBI)

The guidance is based on evolving information and will be updated as new data emerge. It should be read in conjunction with the following documents:

[Information for healthcare professionals on blood clotting following COVID-19 vaccination - GOV.UK \(www.gov.uk\)](https://www.gov.uk/government/guidance/information-for-healthcare-professionals-on-blood-clotting-following-covid-19-vaccination)

[Guidance-version-13-on-management-of-thrombosis-with-thrombocytopenia-occurring-after-c-19-vaccine_20210407.pdf \(b-s-h.org.uk\)](https://www.bsh.org.uk/guidance-version-13-on-management-of-thrombosis-with-thrombocytopenia-occurring-after-c-19-vaccine_20210407.pdf)

Definition of VITT

VITT is defined as a thromboembolic event, in combination with thrombocytopenia, occurring between 5 and 28 days following COVID-19 vaccination¹. VITT shares some hallmarks with heparin-induced thrombocytopenia (HIT), suggesting that an immunological event is the trigger². VITT thromboses typically affect unusual sites. It has been most associated, to date, with the AstraZeneca vaccination^{3,4} but has also been reported after vaccination with the Johnson & Johnson COVID-19 vaccine that also uses an adenovirus vector².

Immune thrombocytopenia without thrombosis has been reported after all COVID-19 vaccines including Moderna and Pfizer vaccines⁵.

Background

COVID-19 infection is itself associated with a high risk of venous thromboembolism (VTE), with 1 in 5 patients admitted to hospital experiencing VTE complications⁶.

In contrast, VITT is a rare adverse event after COVID-19 vaccination². Cerebral venous sinus thrombosis is the most common site (50%) followed by splanchnic vein thrombosis (30%)⁷. Pulmonary embolism and arterial ischaemia have also been reported.

As of 4 April 2021, a total of 169 cases of cerebral venous sinus thrombosis and 53 cases of splanchnic vein thrombosis had been reported via the European Union drug safety database EudraVigilance in a vaccinated population of around 34 million people by that date⁴.

By 21 April 2021, the Medicines and Healthcare products Regulatory Agency (MHRA) in the UK had received notification of 209 cases of thrombosis with thrombocytopenia, including 41 deaths, after administration of 22 million first and 4.4 million second doses of the AstraZeneca vaccine⁸.

The syndrome affects both genders equally but may disproportionately affect younger individuals, in whom the risk of morbidity and mortality from COVID-19 infection is lower.

VITT has typically been reported after the first dose of COVID-19 vaccine but there are also unconfirmed reports after the second dose.

Splanchnic vein thrombosis should be considered and excluded in patients presenting with abdominal pain and thrombocytopenia between 5 and 28 days following COVID-19 vaccination.

Clinical Features

- Presentation with **abdominal pain and thrombocytopenia within 5 to 28 days of COVID-19 vaccination**.
- Abdominal pain may be associated with diarrhoea, fever, jaundice, shortness of breath or altered mental status.
- Bleeding complications in some patients.

Other Presentations

- Incidental finding of splanchnic vein thrombosis on cross sectional imaging for other indications within 28 days of COVID-19 vaccination.
- Detection of splanchnic vein thrombosis on abdominal imaging performed in confirmed case of cerebral venous sinus thrombosis due to VITT as per current Expert Haematology Panel advice ¹.

Laboratory Findings

- Thrombocytopenia with platelet count $< 150 \times 10^9/\text{litre}^1$.
- D-dimer levels $> 4000 \mu\text{g}/\text{litre}$. Patients with D-dimer levels of 2000 - 4000 $\mu\text{g}/\text{litre}$ should be treated as probable cases¹. D-dimer levels are often high in patients with an acute abdomen and so the test may not be helpful in this setting, where the patient would usually undergo radiological investigation anyway. However, a low D-dimer level offers reassurance in patients with non-specific abdominal pain and normal platelet counts who are concerned about VITT.
- Antibodies to Platelet Factor 4 (PF4)⁹ on ELISA heparin-induced thrombocytopenia (HIT) assay ¹. **PF4 antibodies will not be detected by other forms of HIT assay.**

The PF4 antibody result is not always immediately available to confirm the diagnosis and so patients with abdominal pain and thrombocytopenia within 5 to 28 days of COVID-19 vaccination need early imaging to exclude splanchnic mesenteric thrombosis.

Radiological Investigations

If no clinical or haematological features of VITT are present, abdominal symptoms should be managed and investigated via usual care pathways with imaging used as clinically appropriate.

In patients with **abdominal symptoms and thrombocytopenia within 5 to 28 days of COVID-19 vaccination**, early imaging is essential to minimise morbidity and guide clinical management. CT is widely available and is the preferred investigation in this clinical setting. Contrast enhanced CT of the abdomen and pelvis is highly accurate for diagnosing vessel thrombosis and end organ complications or compromise (e.g., mesenteric ischaemia, infarcted bowel, solid organ infarcts)¹⁰. The presence of portosystemic collaterals (varices) is not in keeping with acute splanchnic venous thrombosis, but acute or chronic thrombosis should be considered.

Dedicated abdominal and pelvic MR angiography/venography may be an alternative, especially in younger patients, but should only be used if readily available. MRI may have lower sensitivity than CT, particularly for smaller thrombi.

Doppler ultrasound and contrast enhanced ultrasound have reasonable sensitivity for portal vein thrombosis but are inferior to contrast enhanced CT for segmental occlusions and end organ damage or compromise. Cross sectional imaging protocols optimised for confirmation of other diagnoses (e.g., non-contrast enhanced CT KUB, MRCP) are not sensitive for thrombotic complications and are unsuitable investigations in patients with suspected VITT.

Principles of Management

The role of the emergency surgeon or physician is to maintain a high index of suspicion in patients with abdominal pain who have recently been vaccinated against COVID-19 and to facilitate an early diagnosis with checking a full blood count (FBC) for thrombocytopenia and highlighting suspected VITT to radiology colleagues.

Management of suspected or confirmed cases of VITT requires specialist multidisciplinary care involving emergency medicine, haematology, surgery, gastroenterology, hepatology, radiology, interventional radiology and critical care.

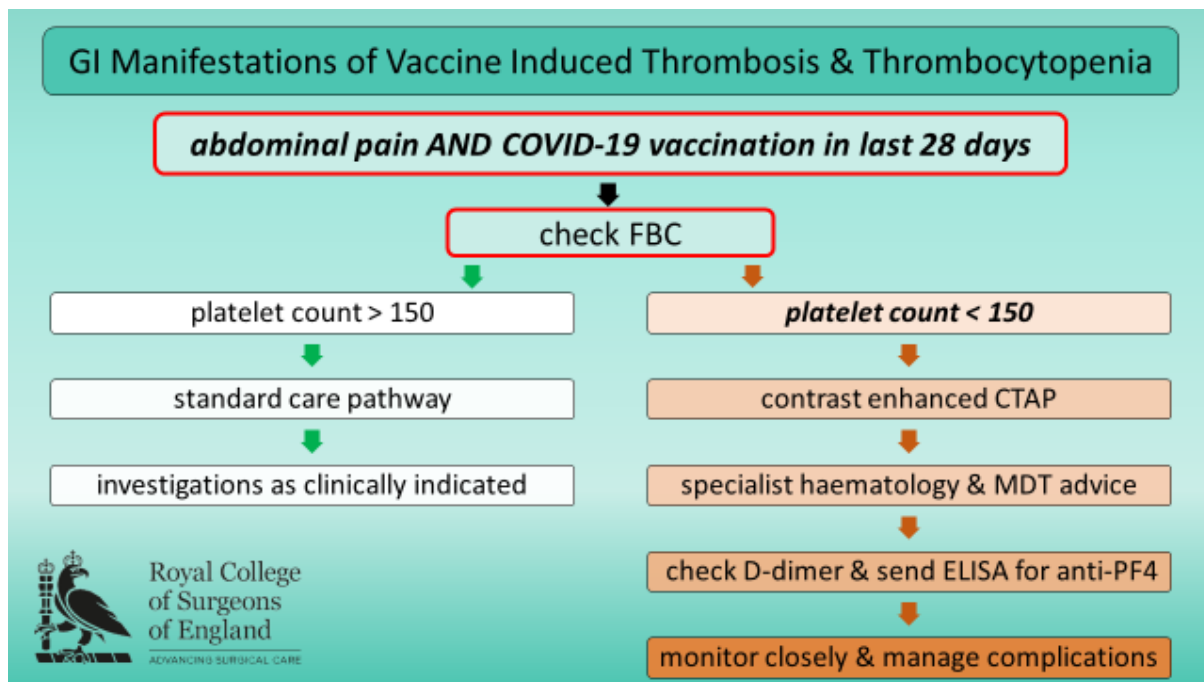
Specialist haematological advice is essential ¹. The Expert Haematology Panel's advice on management of VITT, that is regularly updated, is available here:

https://b-s-h.org.uk/media/19530/guidance-version-13-on-mngmt-of-thrombosis-with-thrombocytopenia-occurring-after-c-19-vaccine_20210407.pdf.

The current key aspects of haematological management of VITT include:

- Intravenous immunoglobulin as soon as possible after diagnosis
- Avoiding platelet transfusion and heparin
- Correction of low fibrinogen levels
- Anticoagulation with non-heparin-based therapy

Ongoing careful clinical and radiological assessment is required to monitor for potential end organ ischaemia and determine need for surgical and/or radiological intervention.



Proposed treatment algorithm for patients presenting with abdominal pain and suspected VITT within 28 days of COVID-19 vaccination

Surgical Intervention

In patients with clinical or radiological evidence of bowel ischaemia (rather than infarction) due to portal vein thrombosis, clinical teams are advised to discuss the option of thrombolysis to restore perfusion with a regional specialist centre prior to undertaking any surgical intervention.

Emergency laparotomy with critical care support on the National Emergency Laparotomy Audit (NELA) pathway is indicated for patients with infarcted or perforated bowel requiring resection.

Second look laparotomy should be considered in patients with evolving venous ischaemia to allow further resection when indicated or, in carefully selected cases, restoration of intestinal continuity in the stabilised and recovering patient.

If total enterectomy is indicated, advice should be sought from national intestinal failure units about suitability for long-term parenteral nutrition and from small bowel transplantation centres about surgical decision-making on cholecystectomy, optimal duodenal drainage and colonic mucous fistula at second look laparotomy to minimise long-term morbidity.

Delayed splenic rupture is a rare complication of splenic infarction due to splanchnic vein thrombosis, and usually requires splenectomy.

Radiological Intervention

There is early data to suggest that systemic thrombolysis under specialist haematological guidance and/or transjugular intra-hepatic systemic shunt (TIPSS) with catheter directed thrombolysis may be beneficial in selected patients with acute occlusive portal or porto-mesenteric venous thrombosis.

The purpose is to restore vessel patency as bowel rescue in the context of intestinal ischaemia, and to minimise the long-term complications of non-cirrhotic portal hypertension when splanchnic vessel thrombosis is extensive.

Such interventions are considered on a case-by-case basis by specialist TIPSS centres and intervention may be offered to a subset of patients¹¹.

In the event of splanchnic vein thrombosis causing bowel ischaemia without infarction, urgent referral to a specialist TIPSS centre is advised. Early contact with the specialist centre is also advised for patients with extensive acute splanchnic vein thrombosis.

National guidance and referral pathways are in development and will be referenced by link in the next version of this document.

Research Samples

Send samples of serum to Colindale for COVID-19 antibody testing and EDTA for whole genome sequencing (consent required) as per Expert Haematology Panel guidance 1.

Notifications Required

All cases of proven and probable VITT should be notified through these portals:

- National Expert Haematology Panel and Public Health England
<https://snapsurvey.phe.org.uk/snapwebhost/s.asp?k=161706705032>
- MHRA Yellow Card
<https://coronavirus-yellowcard.mhra.gov.uk/>

Organ Donation & Transplantation

The recommendations from NHS Blood & Transplant on organ donation and transplantation from patients with VITT, based on concerns about passenger lymphocyte syndrome in transplant recipients, is available here:

<https://nhsbtdbe.blob.core.windows.net/umbraco-assets-corp/22975/inf1569.pdf>

Follow-up

Specialist haematology follow-up is required to monitor platelet counts and symptoms, allow early intervention in event of relapse and advise on anticoagulation.

All patients with splanchnic vein thrombosis should also be referred to the local hepatology team. Repeat CT is recommended 6 months after diagnosis to determine development and extent of chronic splanchnic venous thrombosis. The development of chronic thrombosis requires long term follow up for complications of portal hypertension¹².

Contributing Authors

Nicola Fearnhead (RCSE, RCSEd)
Beverley Hunt (EHP)
Stuart Taylor (BSGAR)
Joanna Leithead (BASL)
Andrew Butler
David Patch
Guruprasad Aithal (BASL)
Michael Davies (ACPGBI)
Philip Haslam (BSIR)
Katherine Henderson (RCEM)
Michael Jenkins (VSGBI)
Sonia Lockwood (ASGBI)
Alastair McKinlay (BSG)
Philip Newsome (BSG)
Giles Toogood (AUGIS)
Andrew Veitch (BSG)

References

1. Expert Haematology Panel. Guidance produced from the Expert Haematology Panel (EHP) focussed on Covid-19 Vaccine Induced Thrombosis and Thrombocytopenia (VITT). 2021; https://b-s-h.org.uk/media/19530/guidance-version-13-on-mngmt-of-thrombosis-with-thrombocytopenia-occurring-after-c-19-vaccine_20210407.pdf.
2. Smadja DM, Yue QY, Chocron R, Sanchez O, Lillo-Le Louet A. Vaccination against COVID-19: insight from arterial and venous thrombosis occurrence using data from VigiBase. *Eur Respir J*. 2021.
3. Schultz NH, Sorvoll IH, Michelsen AE, et al. Thrombosis and Thrombocytopenia after ChAdOx1 nCoV-19 Vaccination. *N Engl J Med*. 2021.
4. AstraZeneca's COVID-19 vaccine: EMA finds possible link to very rare cases of unusual blood clots with low blood platelets [press release]. 07/04/2021 2021.
5. Lee E-J, Cines DB, Gernsheimer T, et al. Thrombocytopenia following Pfizer and Moderna SARS-CoV-2 vaccination. *American Journal of Hematology*. 2021;96(5):534-537.
6. Jevnikar M, Sanchez O, Chocron R, et al. Prevalence of pulmonary embolism in patients with COVID 19 at the time of hospital admission. *Eur Respir J*. 2021.
7. Cines DB, Bussel JB. SARS-CoV-2 Vaccine-Induced Immune Thrombotic Thrombocytopenia. *N Engl J Med*. 2021.
8. Coronavirus vaccine - weekly summary of Yellow Card reporting [press release]. updated 29 April 2021.
9. Scully M, Singh D, Lown R, et al. Pathologic Antibodies to Platelet Factor 4 after ChAdOx1 nCoV-19 Vaccination. *N Engl J Med*. 2021.
10. Kawata E, Siew DA, Payne JG, Louzada M, Kovacs MJ, Lazo-Langner A. Splanchnic vein thrombosis: Clinical manifestations, risk factors, management, and outcomes. *Thromb Res*. 2021;202:90-95.
11. Benmassaoud A, AlRubaiy L, Yu D, et al. A stepwise thrombolysis regimen in the management of acute portal vein thrombosis in patients with evidence of intestinal ischaemia. *Aliment Pharmacol Ther*. 2019;50(9):1049-1058.
12. EASL Clinical Practice Guidelines: Vascular diseases of the liver. *Journal of Hepatology*. 2016;64(1):179-202.